Oral and Maxillofacial Surgery DEN318Y

September 2024

# PRINCIPLES OF SURGERY

Ref:
1. Milloro-Peterson's Principles of Oral and Maxillofacial Surgery Vol I Ch 1
2. J Hupp, E Ellis III, M Tucker. Contemporary Oral Maxillofacial Surgery Ch 3
3. Handout;

Dr Marco Caminiti
Associate Professor
Head and Program Director: Oral and Maxillofacial Surgery
University of Toronto

# THE PRINCIPLES OF SURGERY

## SURGERY DEFINITION

A specific definition for surgery is challenging. Surgery is considered to be the branch of medicine concerned with the art of practice or work of treating diseases, injuries, or deformities by manual or operative procedures. These procedures are generally performed by a surgeon and take place within surgical operating theaters or rooms.

## ORAL AND MAXILLOFACIAL SURGERY

This is the specialty related to the treatment of many diseases and injuries and defects within the head, neck, face, jaws, and hard and soft tissues of the oral cavity and maxillofacial region. It's an internationally-recognized specialty with medical and dental specialization in most parts of the world and recognized as a specialty in dentistry in North America.

The principles of surgery or an introduction to surgery will encompass a wide variety of topics. The term "surgery" incorporates a broad perioperative period of time of which the actual surgical intervention is placed centrally within this timeframe.

## PRESURGICAL PHASE

The presurgical phase includes the ability to differentiate a proper diagnosis and develop an adequate treatment plan. This treatment plan needs to be based on current and best practices that are developed through rigorous training and peer review. The preoperative surgical team gets involved in order to prepare patients from an educational standpoint on what to expect as a result of surgery and this educational component will also help the patient develop an understanding and therefore the commitment of an adequate and appropriate informed consent.

## POSTOPERATIVE PHASE

There is the postoperative phase which deals with the recovery of the surgical patients and deals with immediate medical postoperative concerns. This may oftentimes affect all patients through a variety of signs and symptoms that need to be understood and indeed teams are required for this. There is also the requirement to provide proper nutrition and analgesia. Postoperative sepsis is a concern that needs to be observed and addressed. There are hematologic problems and other internal medicine issues that require prior knowledge and proper care. In this postoperative phase we also look at outcomes and outcome assessments to better plan for and provide better care for the future health of patients – ie how can we make it better?

## SURGICAL TIME FRAME

The operative period will include many ***factors*** and this is the central theme of this lecture:

1. The operating room theater and its importance and layout as well as preparation is paramount;
2. The ability to provide a sterile or septic technique for minor to major procedures;
3. Knowledge of surgical anatomy;
4. The delivery of proper incisions and flap creation
5. The actual surgery itself which may be ablative, reconstructive and/or a whole host of other procedures that can be done which will be covered over the next year and half;
6. Management of tissues;
7. The instruments, tools and equipment required in order to perform proper techniques;
8. The closing of wounds and the management of defects;
9. Wound healing and knowledge of how tissues behave following traumatic surgical interventions.

### Factor #1 - Operating room theater preparation

When it comes to being prepared for the operating room as a student the most important contribution would be the knowledge of the procedure being performed. If you find yourself within an operating theater within our teaching hospitals, you should be able to prepare yourself in giving an oral presentation of what the case involves. The personnel that you will encounter include the following:

- A scrub nurse that manages the instrumentarium;
- A circulatory nurse that helps with the flow of materials in-and-out and guards towards a sterile technique;
- An anaesthetist who will manage the anaesthesia of the patient;
- A respiratory therapist or nurse assistant who will aid in providing adequate materials for the anaesthetist;
- The surgical team which oftentimes includes a surgical attending with a second surgeon assistant, but in the teaching hospitals the second surgeon assistant may include clinical fellows, chief residents, senior residents, or interns.

Therefore, it is not unusual to be within an operating theater with 6 to 10 other people in the room and it's important that as an observer you understand what procedure is being performed, how it's being performed, and be prepared to give an assessment, and there are plenty of other people within the room that you can gather information from. You should look at your operating room experience as a proactive learning experience rather than one of passive observance.

Factor #2: Sterile technique or aseptic technique

This has been fine-tuned for the past 200 years and it wasn't really until the late 1800's when pathogens were recognized as post-operative problems in managing any surgery. The goal within the operating room theater is to have everything surgically clean and sterile. The instruments are sterile. The trays are sterile. The patient is placed on a bed and then draped and covered with sterile solution. The surgeon and assistants wear sterile gloves and sterile gowns. The face and the hair are covered. Nurses will also be aware of sterile technique and in the event of a break within the sterile technique there are immediate mechanisms in place in order to clean, change or cover certain fields.

The rationale in an oral surgeon's general office however is a little bit less clear and indeed current controversies even within the province of Ontario with Public Health have shed a light on some of the difficulties in defining the level of sterility that's required in the office. The office situation is meant to eliminate cross-contamination of patients, but the level of an operating room sterile technique is not necessary.

Some definitions to understand:

- "Sepsis" means the breakdown of living tissue by pathogens. It is accompanied by inflammation;
- "Medical asepsis" is the attempt to keep patients, healthcare staff and objects as free as possible from these pathogens;
- "Surgical asepsis" is the attempt to prevent microbes from gaining access into wounds to avoid postoperative infections.

In the office, a clean technique is required to decrease the microbial load and also eliminate cross-contamination. In a clean technique underclothing should be covered by long-sleeved garments. Hands must be washed prior to each patient or the use of a hand sanitizer is adequate. Clean gloves must be worn in order to avoid cross-contamination.

However, if a procedure does have greater invasiveness of the tissues and/or there's increased risk of bleeding, then it is wise to don surgical gloves and try to maintain a sterility of all exposed surfaces. Eye protection, face mask, and draping of the patient are especially important to decrease any contaminations and cross-contaminations. Wounds are also cleaned with sterile water or sterile saline solution in order to irrigate wounds, irrigate the drilling, and eliminate debris as much as possible.

Factor #3: Knowledge of surgical anatomy

It is said that *surgery is anatomy* in that the knowledge required of an individual to perform manual tasks in removing, fixing, repairing, or reconstructing tissues requires

intimate knowledge of the anatomic regions. You will see this evidenced by the constant quizzing of junior residents with regards to anatomic spaces because understanding anatomic spaces, planes, and relationships is critical to avoid damage to critical structures. So if you intend to impress anyone coming into the operating room, make sure you're fully aware of the anatomy of the region.

Factor #4: Incisions

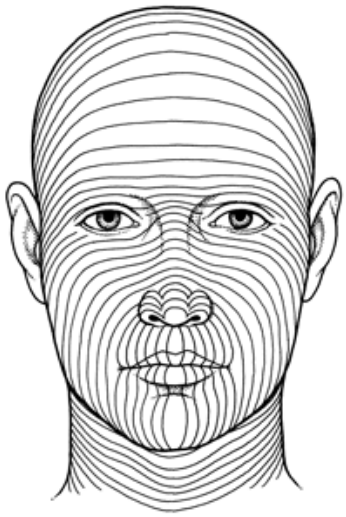

From a basic standpoint, incisions really require the use of a steel blade. They come in many shapes and sizes. These tend to dull very quickly, especially if they touch bone or another hard object, but they are relatively inexpensive and should be used liberally when making cuts. The creation of the incision does require a smooth continuous stroke, generally brought towards you with the smoothest of motions, and you also have to avoid small sharp short little cuts which produce greater surface area of the wound which means greater risk of bleeding. It is also important to create incisions that will allow for proper closure afterwards. Oftentimes we may consider incisions in certain strategic areas knowing full well that we'll have to close the tissue afterwards and eliminate the risk of tension and ischemia across these wounds. (eg Lines of Langerhans)

The types of intraoral incisions include the following:

- Straight vertical incisions;
- Straight horizontal incisions;
- Interpapillary incisions or sulcular incisions or gingival margin incisions which are carried out using a scalpel at a reverse bevel in the interdental papilla and sometime in the super-crestal trans-septal fibers of the periodontal ligament being incised;
- A gingival marginal incision is sometimes fabricated. This incorporates releasing incisions in order to widen the base at the apex, or these vertical incisions may be eliminated in order to minimize aesthetic changes that might occur within the healing of that vertical incision;
- Releasing incisions can be made at the end of gingival marginal or sulcular incisions and this will greatly improve the visibility and also protects the vascularity of the flap;

- There are other types of angled incisions that are used in the corners of the mouth or over top of tori and these are intentionally made in order to allow for proper closure afterwards. The textbooks contain many illustrations and drawings of the different variations but the major limits when dealing with raising a flap include the following:

- The flap base dimension must not be less than the height dimension and preferably it should two times as wide as the height is long;
- A releasing incision needs to be made to ensure that there isn't a cut-off of the blood supply. If these releasing incisions are performed obliquely, an oblique direction increasing the base should be performed;
- Flaps need to be undermined in order to allow for full extension and tension-free closure;
- Once a flap is raised, this tissue has to be properly maintained and minimal trauma should be placed on the flap to avoid any button holes or tearing if it's stretched too much which can be very problematic.

There are a variety of different flaps but in general they are named by the description of the shape they form;

- Envelope or sulcular flap;
- Envelope flap with one releasing incision which has 3 corners;
- Envelope flap with two releasing incisions on either side which has 4 corners;
- Semi-lunar flap that's done in a vestibular-type incision;
- Y-incision that can be performed either in the posterior tuberosity or on the palate;
- Pedical flap with the rotation of tissue to cover certain defects and this will be shown in later lectures.

The reason so much emphasis is placed on maintenance of flap is that oftentimes there are a number of complications may occur, including:

- Flap necrosis;
- Flap dehiscence;
- Flap tearing;
- Injury to local structures.

In general, these complications can be avoided by ensuring a broad-base, tension-free closure, good blood supply to the flap, ensuring that suturing does not take place over dead space or a defect, the gentle handling of these flaps, ensuring there are no button holes or tears, and knowledge of the anatomy which provides for a better blood supply and tension-free closure;

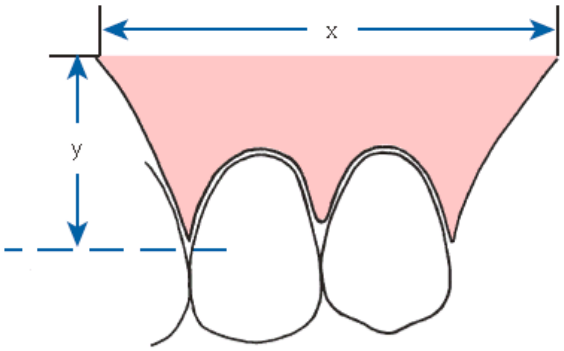

Factor #5: The surgery

A short video will be shown in-class regarding a specific type of osteotomy performed within the maxillofacial region. The surgery will include simple procedures such as minor gingivectomies, the creation of small flaps in the periodontal area to close defects, the removal of teeth, the removal of roots, the removal of impacted teeth, the exposure of teeth and unerupted teeth, performance of small incisional biopsies, the performance of excisional biopsies and so on. Over the course of the next year and half, the different types of surgeries will be demonstrated and laboratory exercises for the group will also be available for your practice.

Once the surgery is complete or being completed, wound management strategies are then implemented. We briefly spoke about the management of the flaps but in general the post-surgical procedure tissue management includes the knowledge of obtaining proper hemostasis, application of dressings or bandages, compression and mimizing stressors on the wound (pressure, shearing forces, excess swelling).

Hemostasis of wounds will oftentimes require several attempts to either slow down minor typical and expected oozes as well as the management of brisk and serious bleeding. Hemostasis includes the following:

- Application of pressure using either gauze packs or clamping the vessels with hemostats and in general this attempt between 1 to 10 minutes is all that's required in order to have small capillary bleeding stop. It is important that while applying these packs there is no motion, streaking or wiping of the tissues because this will start the bleeding up again;
- A second method that's commonly used in the operating room and in some surgical clinics is the use of heat to stop blood flow in generally either an electric current using electrocautery or radiofrequency ablation, or sometimes (but infrequently) laser ablation. All these are useful to coagulate blood vessels;
- Another common quick method to stop bleeding is by suture ligation within soft tissues. This is simply a matter of a figure-8 suture within the tissues held tightly in order to obstruct any blood flow from continuing to the bleeding site;
- A final method of hemostasis is the ability to apply some chemical cautery with vaso-constrictors, topical agents (silver nitrate) and direct coagulants.

Factor # 6: Management of tissues

Tissue management also includes what to do with space that's created after the elimination of a defect. In certain sites, the extraction of teeth does require management of this dead space. Luckily the socket will form a plug which coagulates and that dead space will be filled by a coagulum but as you know if this coagulum is lost a dry socket can form which is a very uncomfortable painful situation and this will be

covered fully later on, but a dry socket is an example of what happens when dead space is not properly managed.

For certain defects such as a dead spaces, we have to either pack them with gauze or pack them with bone to eliminate the risk for hematomas which can get infected. The proper suturing of flaps in order to avoid the collapse of a dead space is also important. Oftentimes we also place small rubber drains within the dead space that will pull out any blood that's coagulating and cause a suction-type effect allowing for full coverage of soft tissue around the defect.

<u>Factor #7: Instruments</u>

Surgical instruments are a key aspect and important to all surgical practices. This includes a general practitioner's dental office. Every single procedure you perform requires proper knowledge of the instruments and handling of the instruments. Everyone has their own favorite set of tools that they develop over time, but in general an oral surgical instrument tray will include an instrument to incise which includes steels blades or electric cautery, instruments to reflect tissues such as Minnesota's or Seldin's, instruments to grab tissues such as hemostats, snaps or Kelly, instruments to manipulate and reflect gingival tissues such as a Woodson or a #9 periosteal elevator, instruments used to trim bone which include either rongeurs or power instruments, and finally instruments that aid in debridement such as curettage and closures such as needle drivers and sutures.

Each one of these will be described in detail in each section as we move along during the course of the year. At this stage, it's important to point out the use of power instruments with regards to the cutting of bony tissues. It's very important not to use your dental drill that is used as compressed air to spin a small turbine, but if this same compressed air falls underneath tissue or indeed within the bone marrow spaces this can produce life-threating emphysema (example will be shown in class).

Rotary instrumentation can be extremely dangerous to patients with regards to adjacent tissue damage as well as other operating staff. Great care must be taken prior to the use of power instrumentation. Therefore, it's imperative that when an instrument is provided it is used appropriately.

Factor # 8:  Closing wounds

The ability to coapt tissues back to their normal position is important and has multiple functions.  Suturing allows the wound margins to come together and to be held in place. It allows for the best environment for wound healing.  Sutures also aid in repositioning tissues in areas required for augmentation.  Suturing is also used for utility purposes and the placement of drains, retraction (holding tissue aside), and positioning adjunctive surgical aids during resections, indicating the position of critical structures. As mentioned previously they can be used to tied off vessels for hemostasis.

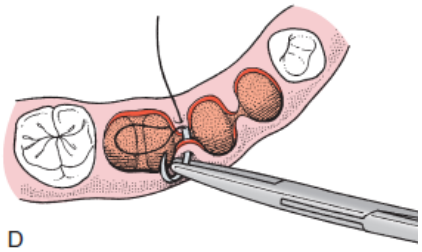


With regards to incised mucosal tissues, the sharper the incision and the less trauma that's inflected, the better the wounds come together.  These 2 wound margins should be minimally damaged.  Wound healing will be rapid and complete.  Any excessive tearing or trauma to the flap and the wound edges will cause greater surface damage and less primary healing.  Suturing also aids in the hemostasis of flaps and will create an area of obtunded tension in order to minimize continuous venous ooze that may occur and eventually bleeding within the soft tissues underneath will be tamponaded by this sutured overlying tissue.

Suturing is also a skill that develops over many years and indeed surgeons well into 20-30 years or practice continually practice to improve their suturing skills.  It's been reported to be analogous to a golf swing where you never really perfect it and there may be days where the swing is better than others!

Other methods of coapting tissue together include stapling, taping, or tissue glues and these will be demonstrated over the course of the year as well.

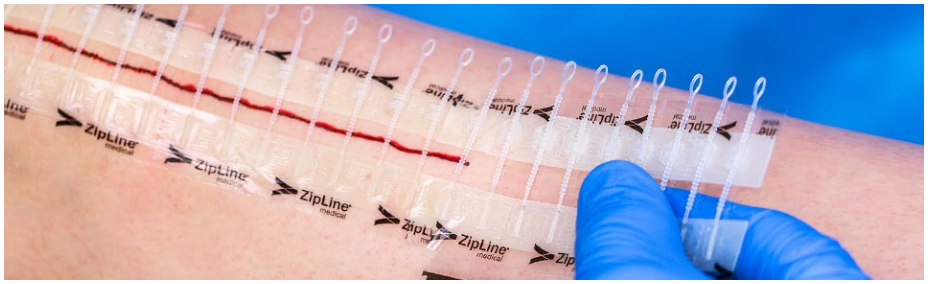

Factor # 9:  Wound healing

Knowledge regarding normal wound healing is essential in order to manage the tissues and all the descriptions we've mentioned previously.  The physiology of wound healing includes the inflammatory phase, the proliferation phase, and the maturation and remodeling phase.

There's also specialized healing that you will encounter within the oral maxillofacial surgery scenario, and this includes extraction of teeth which is quite a unique wound healing process.

There's also specialized healing with regards to skin and oral mucosa which includes grafting of skin.

A final specialized type of healing that you will encounter is with regards to the placement of implants.

There are certain elements where we can improve upon the wound healing which includes the application of growth factors, hyperbaric oxygen therapy, and some skin substitutes and tissues that will be demonstrated.

Further details regarding wound healing will be described in upcoming lectures.

Conclusion:

So as you can see a simple lecture on the "Introductory to Surgery" is merely an attempt to detail a complex "table of contents" as you embark on this fascinating topic. Our goal is to provide a complete introduction to OMFS but as well to teach key skills and reach specific milestones. Our patients depend on us to master many "Entrustable Professional Acts" (EPAs). Essential Oral and Maxillofacial Surgical EPAs that need to be taught for undergraduate dental students include not only the extraction of teeth, but as well the draining of infections, the management of edentulous spaces, the management of oro-facial trauma and pathology.